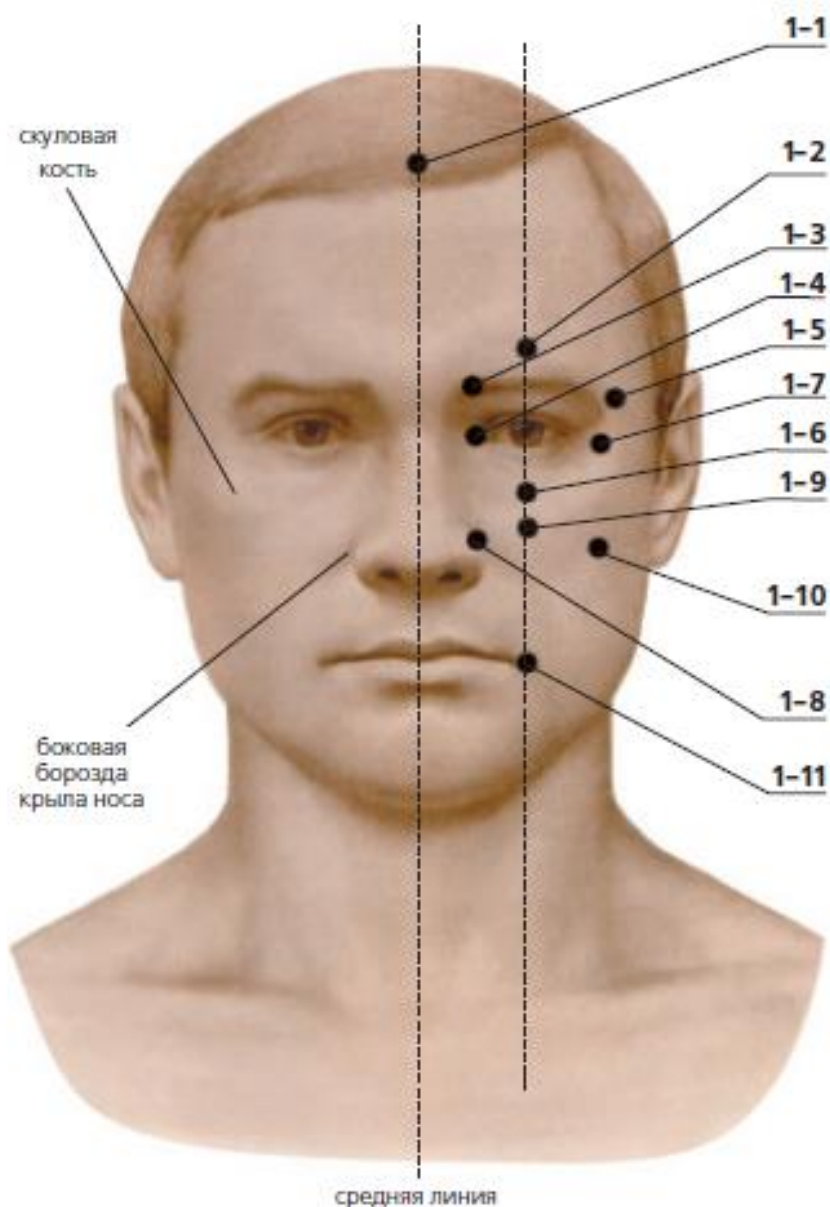


Recommended zones for electromagnetic exposure

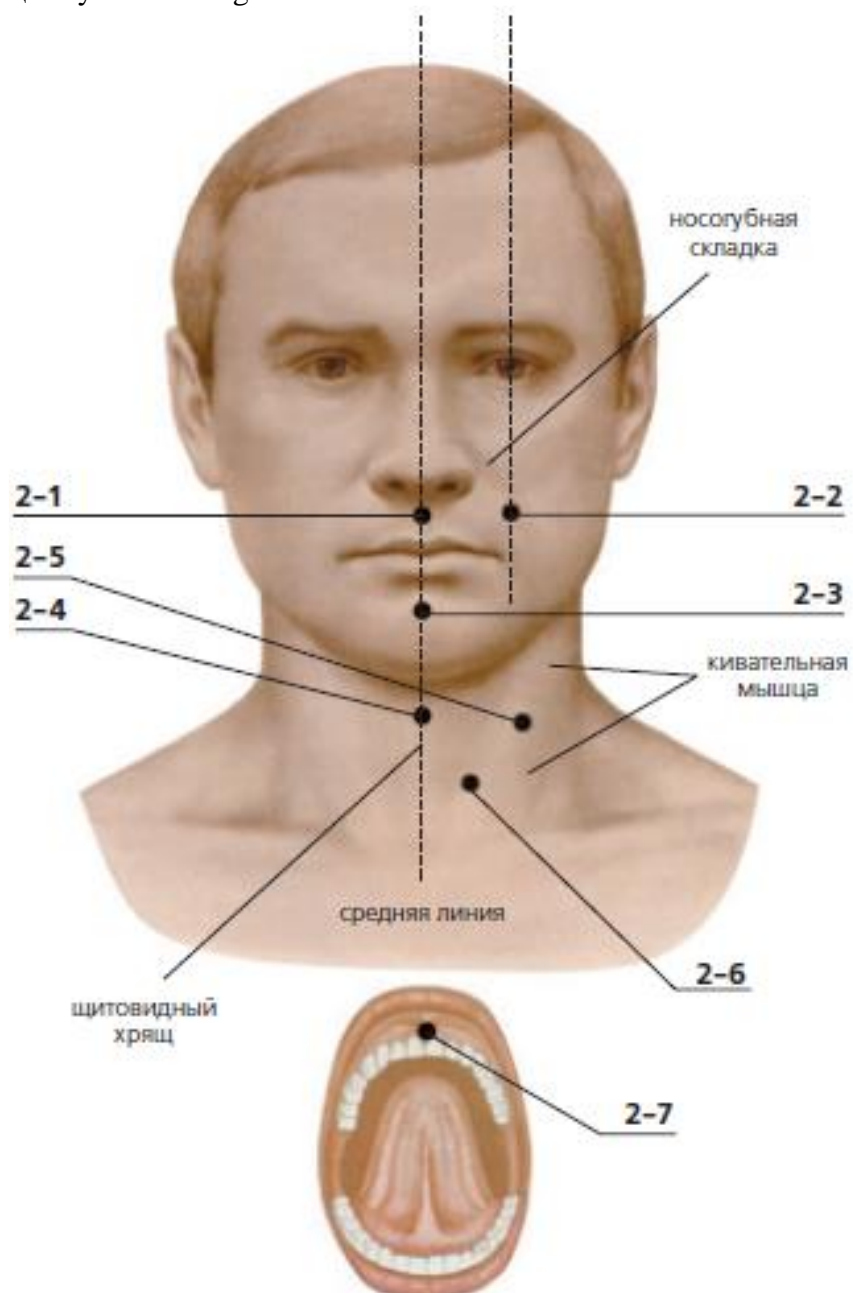
- 1-1** – on midline of the head, 0.5 chon upper from the anterior hair margin
- 1-2** – 1 chon upper from center of eyebrow
- 1-3** – at the beginning of eyebrow
- 1-4** – 3 mm far from internal side of eye to the nose
- 1-5** – at the external end of eyebrow, in fovea
- 1-6** – under the pupil, on the center of lower edge of the orbit
- 1-7** – 5 mm from external angle of the eye
- 1-8** – in the lateral sulcus of wing of nose
- 1-9** – 10 mm below from the 1-6
- 1-10** – in the recess at low margin of zygomatic bone, vertically and lower from external angle of eye
- 1-11** – angle outwards from 1 cm on a vertical line through the pupil.

Скуловая кость (скула) – cheekbone // Боковая борозда крыла носа - lateral sulcus of the wing of the nose // Средняя линия - middle line



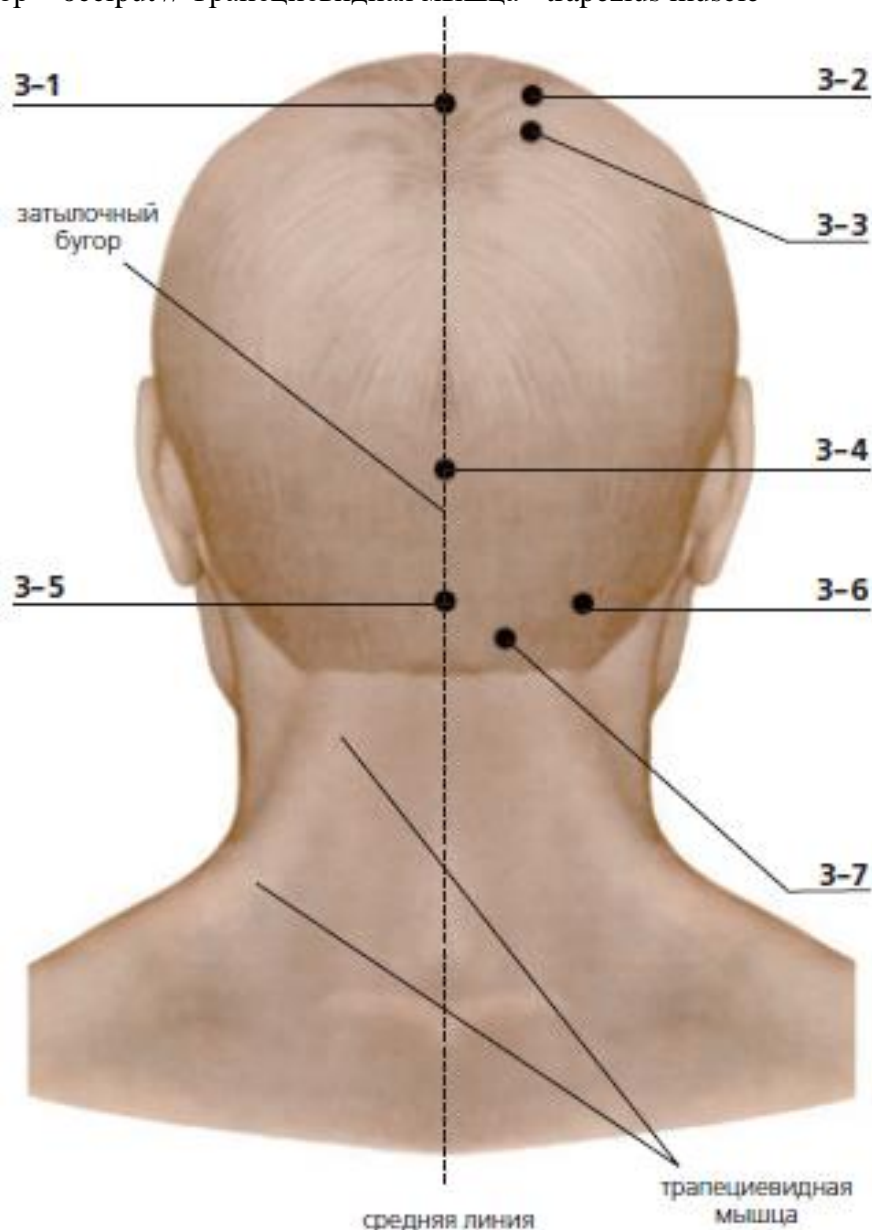
- 2-1 – under the nose, above upper lip, in fovea
- 2-2 – in nasolabial fold on intersection point with vertical line going from the center of pupil
- 2-3 – on the center of chin-lip fold
- 2-4 – on midline 5 mm above from the upper margin of thyroid cartilage
- 2-5 – outside from upper margin of the thyroid cartilage, on the center of sternocleidomastoid muscle
- 2-6 – outside from lower margin of the thyroid cartilage, at anterior margin of sternocleidomastoid muscle
- 2-7 – on the upper gingival margin, on the frenulum of upper lip (on border of transition of a mucous membrane of a upper lip in gum)

Носогубная складка - nasolabial fold // Кивательная мышца - sternocleidomastoid muscle // Щитовидный хрящ - thyroid cartilage



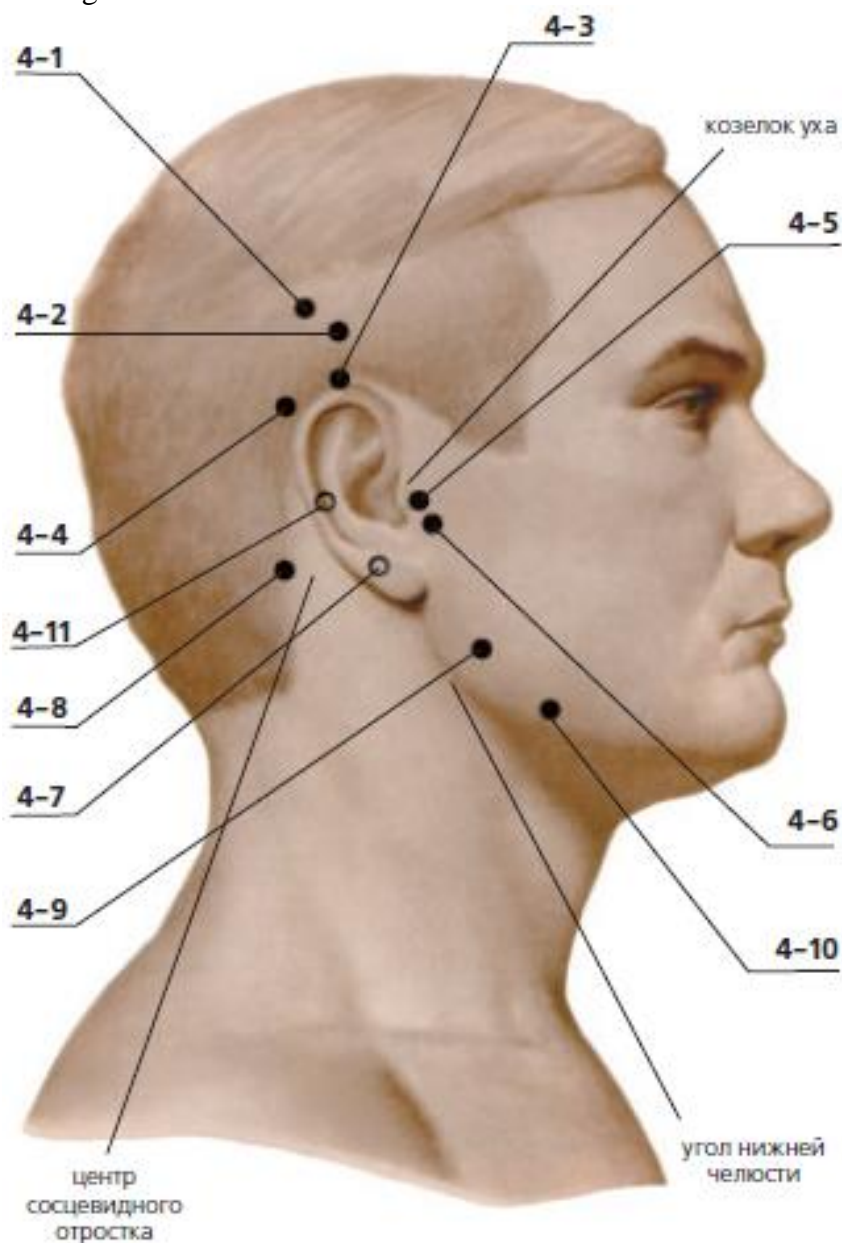
- 3-1** – on midline 7 chon upper from posterior hair margin or 5 chon back from anterior hair margin
- 3-2** – 4 chon back from anterior hair margin and 1,5 chon far from midline of head, on the crown of head
- 3-3** – 5,5 chon back from anterior hair margin and 1,5 chon far from midline
- 3-4** – on midline on the upper margin of occipital tuber, 2,5 chon upper from posterior hair margin
- 3-5** – in occipital fossa
- 3-6** – under occipital bone, at external border of trapezius muscle, on the parallel line to ear lobule, in fossa
- 3-7** – 20 mm upper from posterior hair margin and 1,3 chon far from midline. The area is painful on palpation.

Затылочный бугор – occiput // Трапецевидная мышца - trapezius muscle



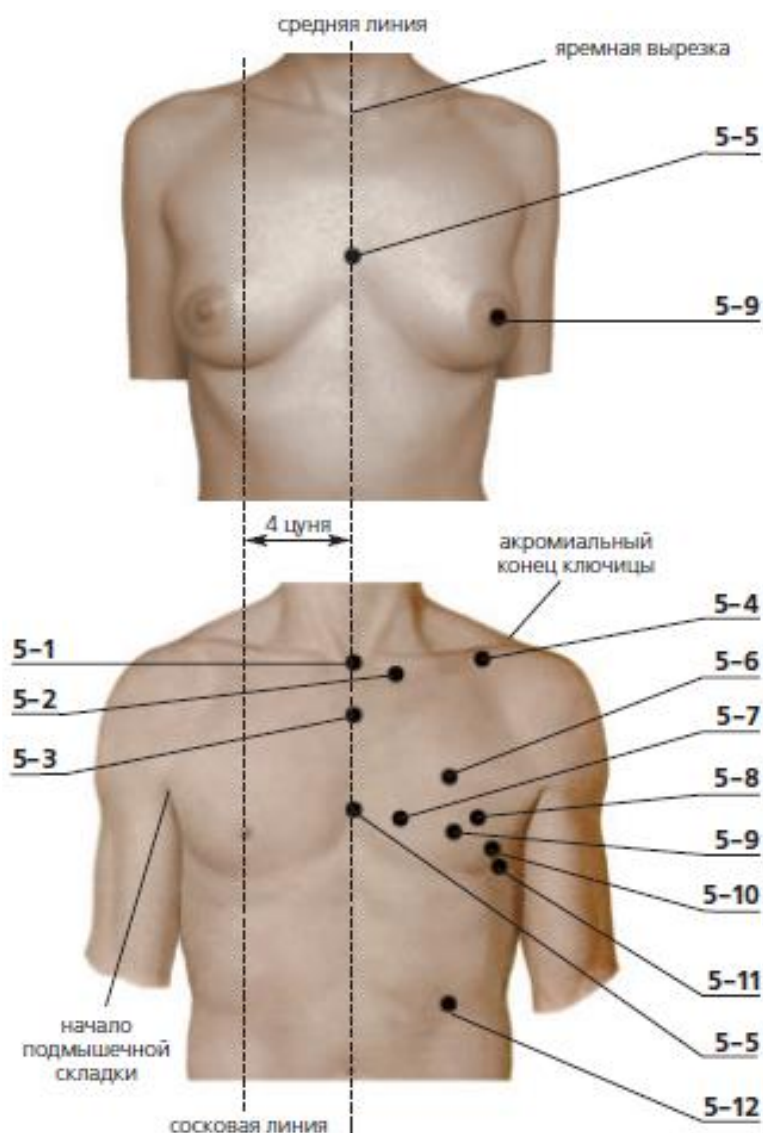
- 4-1** – 2 chon above from upper ear margin, backward, on the vertical line from the center of mastoid process
- 4-2** – 1,5 chon upper from upper ear margin (1,5 chon upper from 4-3)
- 4-3** – at upper ear margin
- 4-4** – 1 chon below from 4-3, behind the ear
- 4-5** – between tragus of ear and mandibular joint, in the fossa when someone opens mouth
- 4-6** – ahead and below from ear tragus, in the fossa
- 4-7** – behind the ear lobule, in fossa
- 4-8** – at posterior margin of mastoid process on horizontal line from area 4-7
- 4-9** – 0,5 chon anteriorly and upper from mandibular angle, in the fossa. The area is painful on palpation.
- 4-10** – 1,3 chon anteriorly from mandibular angle on its low margin.
- 4-11** - behind the ear on the same level with the external auditory opening anteriorly from the base mastoid of the temporal bone.

Козелок уха - tragus ear // Центр сосцевидного отростка - mastoid center // Угол нижней челюсти - mandibular angle



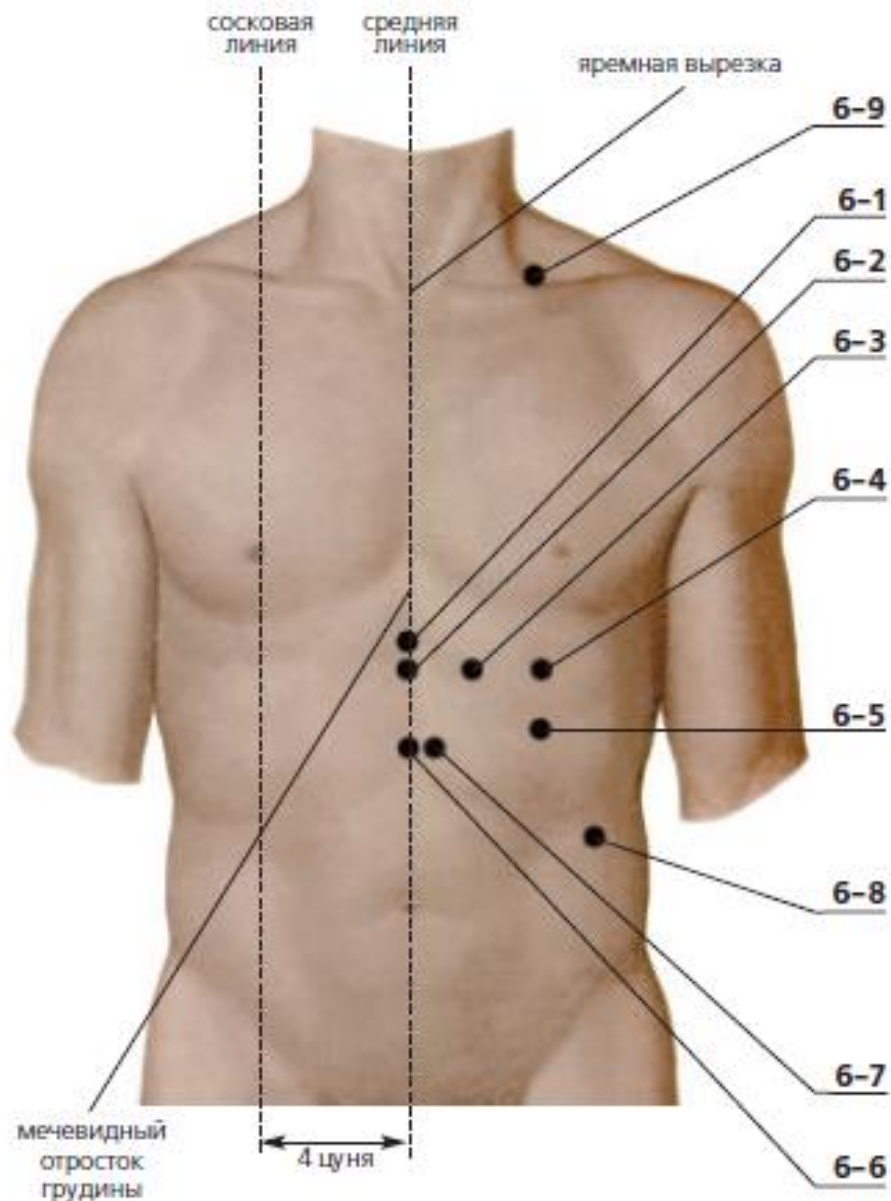
- 5-1** – in jugular notch of sternum, in the fossa
- 5-2** – 2 chon far from midline under clavicle
- 5-3** – on midline 2,5 chon below from jugular notch (from 5-1)
- 5-4** – under the low margin of acromial end of clavicle, in subclavicular fossa.
- 5-5** – on midline, 6 chon below from jugular notch, on the level of 4th intercostal space
- 5-6** – on mammary line, (4 chon far from midline), 4 chon below from clavicle, in 3rd intercostal space. The area is painful on palpation. It is easy to find the point in supine position.
- 5-7** – 2 chon from 5-5 along the rib, in 4th intercostal space. It is easy to find the point in supine position.
- 5-8** – 5 chon from 5-5 along the rib, in 4th intercostal space. It is easy to find the point in supine position.
- 5-9** – in the center of nipple
- 5-10** – 4,5 chon lower from beginning of axillary line in 4th intercostal space. It is easy to find the point in supine position.
- 5-11** – area is detected by intersection point of two lines – 6 chon below from beginning of axillary line and 6 chon far from midline, in 5th intercostal space. It is easy to find the point in supine position.
- 5-12** – above the level of the navel is 3 chon and sides of the midline 4 chon.

Яремная вырезка (впадина) - jugular notch // Акромиальный конец ключицы - acromial end of clavicle // Начало подмышечной складки - beginning of the axillary fold // Сосковая линия - nipple line



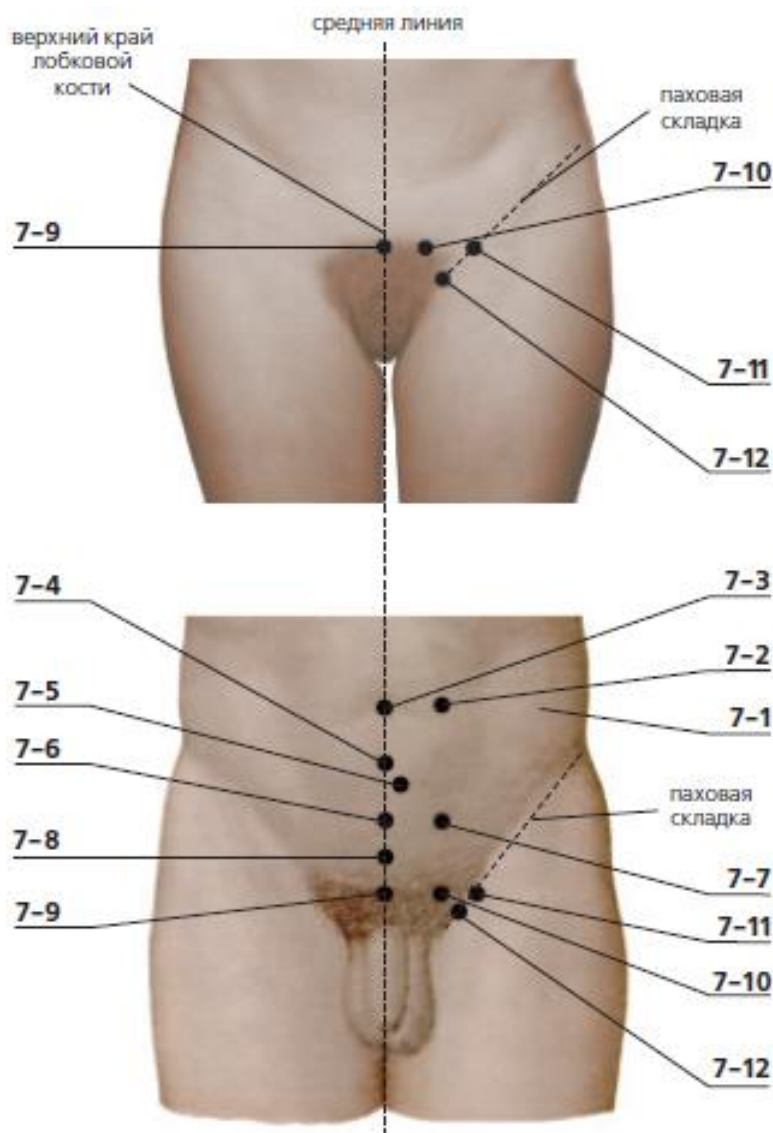
- 6-1** – on midline, 0,5 chon lower from the end xiphoid process, or 7 chon upper from umbilicus
- 6-2** – on midline 1,5 chon lower from xiphoid process of sternum or 6 chon upper from umbilicus
- 6-3** – 2 chon far from midline on the level of 6-2 (the place of attachment 8th rib cartilage to sternum)
- 6-4** – 4 chon far from midline on the level of 6-2, on mammary line (in 6th intercostal space). It is easy to find the point in supine position.
- 6-5** – 4 chon upper from umbilicus and 4 chon far from midline (on mammillary line, in 7th intercostal space). It is easy to find the point in supine position.
- 6-6** – on the midline 4 chon upper from umbilicus. It is easy to find the point in supine position.
- 6-7** – 4 chon upper from the umbilicus and 0,5 chon far from the midline. It is easy to find the point in supine position.
- 6-8** – at free edge of 11th rib. It is easy to find the point in supine position.
- 6-9** – in the center of the subclavian fossa, laterally from the midline chest 4 chon.

Мечевидный отросток грудины - xiphoid process of sternum



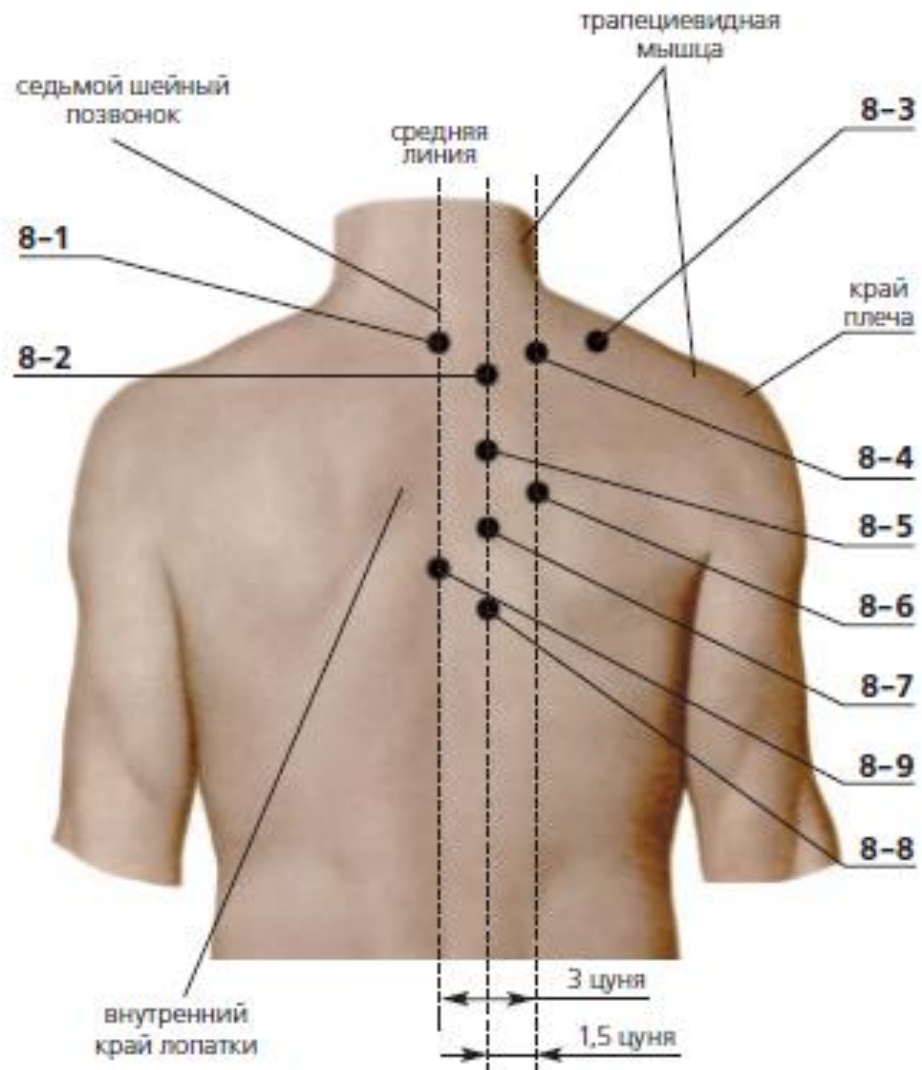
- 7-1** – 6 chon far from umbilicus along the horizontal line (a little below the free edge of 11th rib). It is easy to find the point in supine position.
- 7-2** – 2 chon far from umbilicus along the horizontal line.
- 7-3** – in the center of the umbilicus
- 7-4** – 1,5 chon lower from the umbilicus on midline
- 7-5** – 2 chon lower the umbilicus and 0,5 chon far from midline
- 7-6** – 3 chon lower the umbilicus on midline. It is easy to find the point in supine position.
- 7-7** – 3 chon lower the umbilicus and 2 chon far from midline. It is easy to find the point in supine position.
- 7-8** – 4 chon lower the umbilicus on midline. It is easy to find the point in supine position.
- 7-9** – on the center of upper edge of pubic bone. It is easy to find the point in supine position.
- 7-10** – at upper edge of pubic bone and 2 chon far from midline. It is easy to find the point in supine position.
- 7-11** – in the center of inguinal fold on the parallel line to 7-9 area. It is easy to find the point in sitting position.
- 7-12** - in the middle of the inguinal fold, at the level of the lower edge of the pubic symphysis.

Верхний край лобковой кости - superior edge of the pubic bone // Паховая складка - inguinal fold



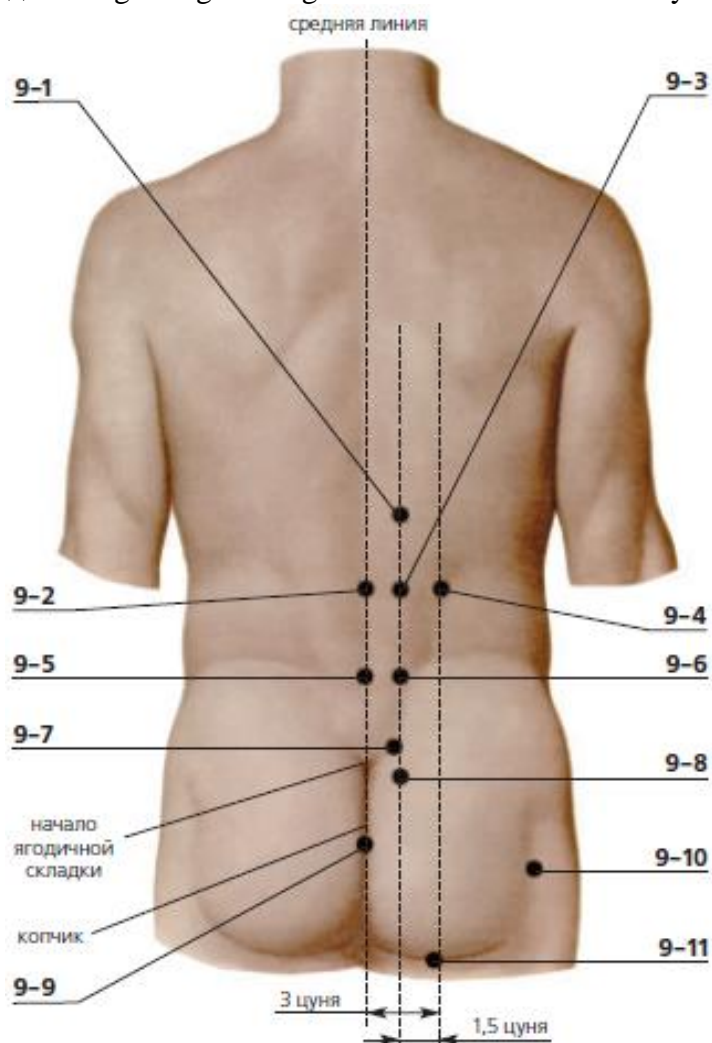
- 8-1** – under cervical (prominent) vertebra between spinous processes of 7th cervical and 1st thoracic vertebra
- 8-2** – between spinous processes 1st and 2nd thoracic vertebrae and 1,5 chon far from midline. It is easy to find the point in prone position.
- 8-3** – on middle of distance between 7th cervical vertebra and shoulder border, on the upper border of trapezius muscle. The point is painful on palpation.
- 8-4** – on the level of spinous process of 1st thoracic vertebra and 3 chon far from midline. It is easy to find the point in prone position.
- 8-5** – between spinous processes of 3rd and 4th thoracic vertebra and 1,5 chon far from midline. It is easy to find the point in prone position.
- 8-6** – between spinous processes of 4th and 5th thoracic vertebra and 3 chon far from midline. It is easy to find the point in prone position.
- 8-7** – between spinous processes of 5th and 6th thoracic vertebra and 1,5 chon far from midline. It is easy to find the point in prone position.
- 8-8** – between spinous processes of 7th and 8th thoracic vertebra and 1,5 chon far from midline. It is easy to find the point in prone position.
- 8-9** – between spinous processes of 6th and 7th thoracic vertebra.

Седьмой шейный позвонок - 7th cervical vertebra // Край плеча - shoulder edge // Внутренний край лопатки - the inner edge of the scapula



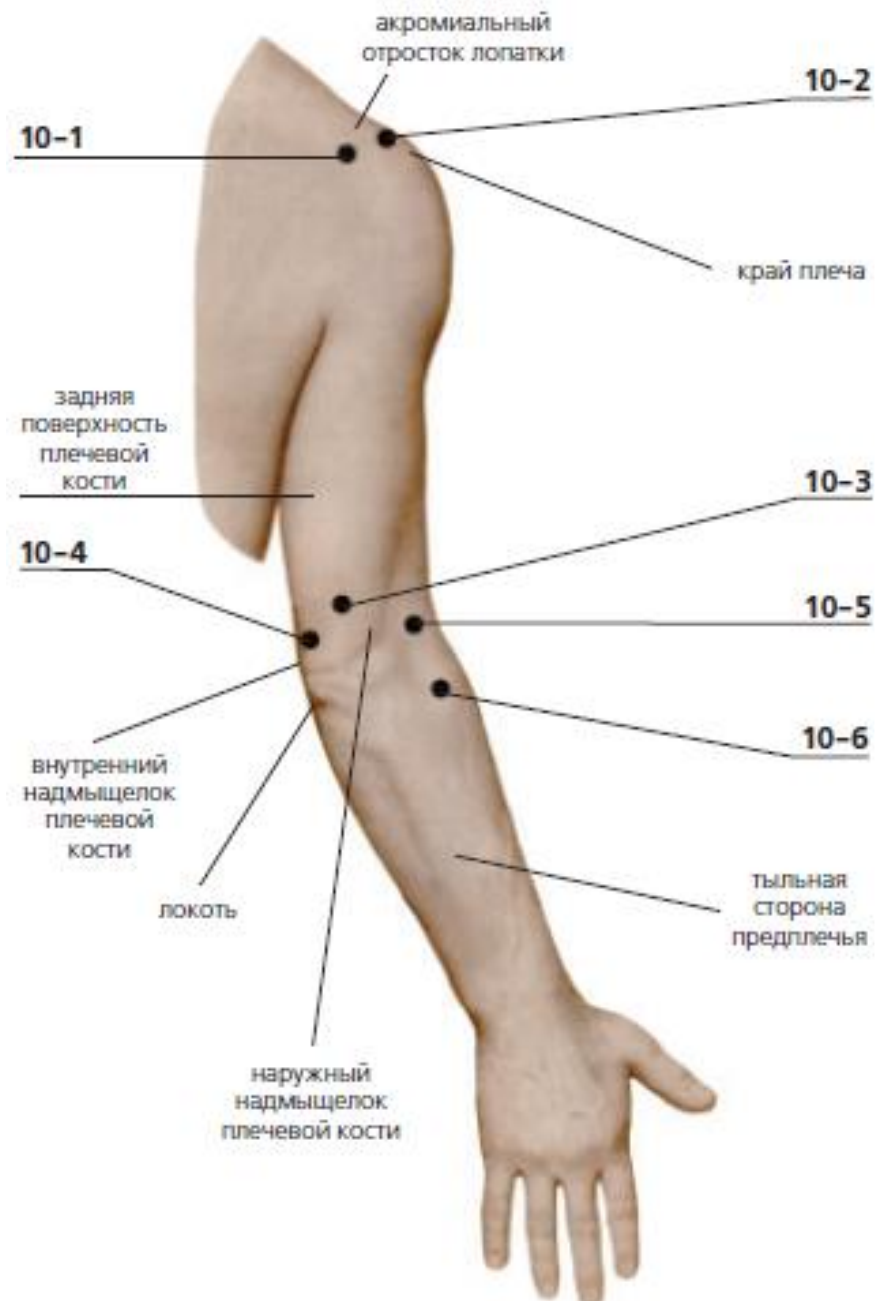- 9-1** – between spinous processes of 12th thoracic and 1st lumbar vertebra and 1,5 chon far from midline. It is easy to find the point in prone position.
- 9-2** – between spinous processes of 2nd and 3rd lumbar vertebra on midline. It is easy to find the point in prone position.
- 9-3** – between spinous processes of 2nd and 3rd lumbar vertebra and 1,5 chon far from midline. It is easy to find the point in prone position.
- 9-4** – between spinous processes of 2nd and 3rd lumbar vertebra and 3 chon far from midline. It is easy to find the point in prone position.
- 9-5** – between spinous processes of 4th and 5th lumbar vertebra, on midline. It is easy to find the point in prone position.
- 9-6** – between spinous processes of 4th and 5th lumbar vertebra and 1,5 chon far from midline. It is easy to find the point in prone position.
- 9-7** – 1 chon upper from beginning of gluteal fold and 1 chon far from midline (on upper edge of sacrum). It is easy to find the point in prone position.
- 9-8** – 1,5 chon lower from beginning of gluteal fold and 1,5 chon far from midline (between spinous processes of 2nd and 3rd sacral vertebra). It is easy to find the point in prone position.
- 9-9** – on midline under coccyx. It is easy to find the point in prone position.
- 9-10** – on buttock behind of hip joint. It is easy to find the point in prone position.
- 9-11** – in the center of subgluteal fold. It is easy to find the point in prone position.

Начало ягодичной складки - beginning of the gluteal fold // Копчик - сосцух



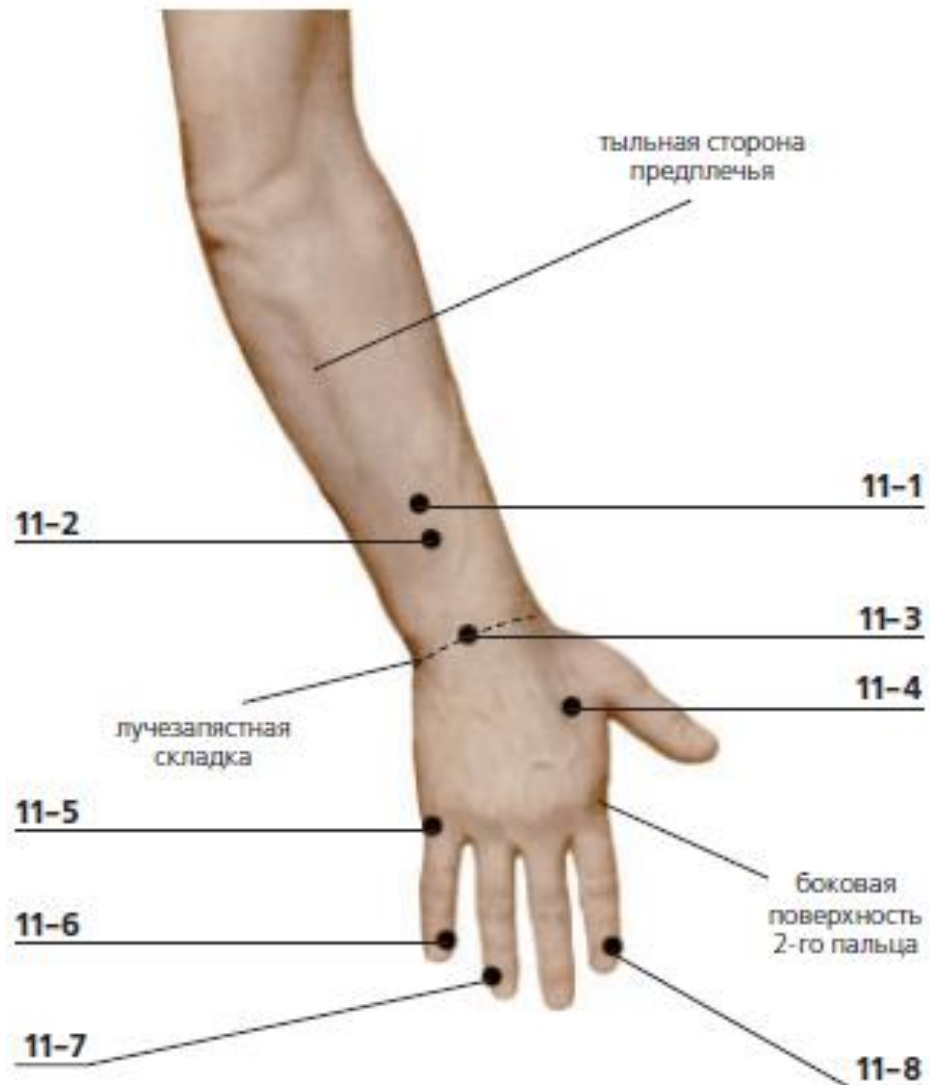
- 10-1** – on the back surface of a humeral joint, under acromion process of scapula
- 10-2** – between acromion process of scapula and greater trochanter of humerus where fossa forms when someone raises the hand
- 10-3** – 2 chon upper from the elbow on posterior surface of humerus, between tendons. The point is painful on palpation.
- 10-4** – in sulcus between elbow and medial epicondyle of humerus. The point is painful on palpation.
- 10-5** – the point is easy to detect at the hand bent in an elbow; 1 chon from the end of skin fold to an elbow
- 10-6** – on the dorsal surface of forearm, 2 chon below from 10-5. The area is painful on palpation.

Акромиальный отросток ключицы – acromial process of clavicle // Задняя поверхность плечевой кости - posterior surface of the humerus // Внутренний надмыщелок плечевой кости - internal epicondyle of the humerus // Локоть - elbow // Наружный надмыщелок плечевой кости - external epicondyle of the humerus // Тыльная сторона предплечья - back side of the forearm



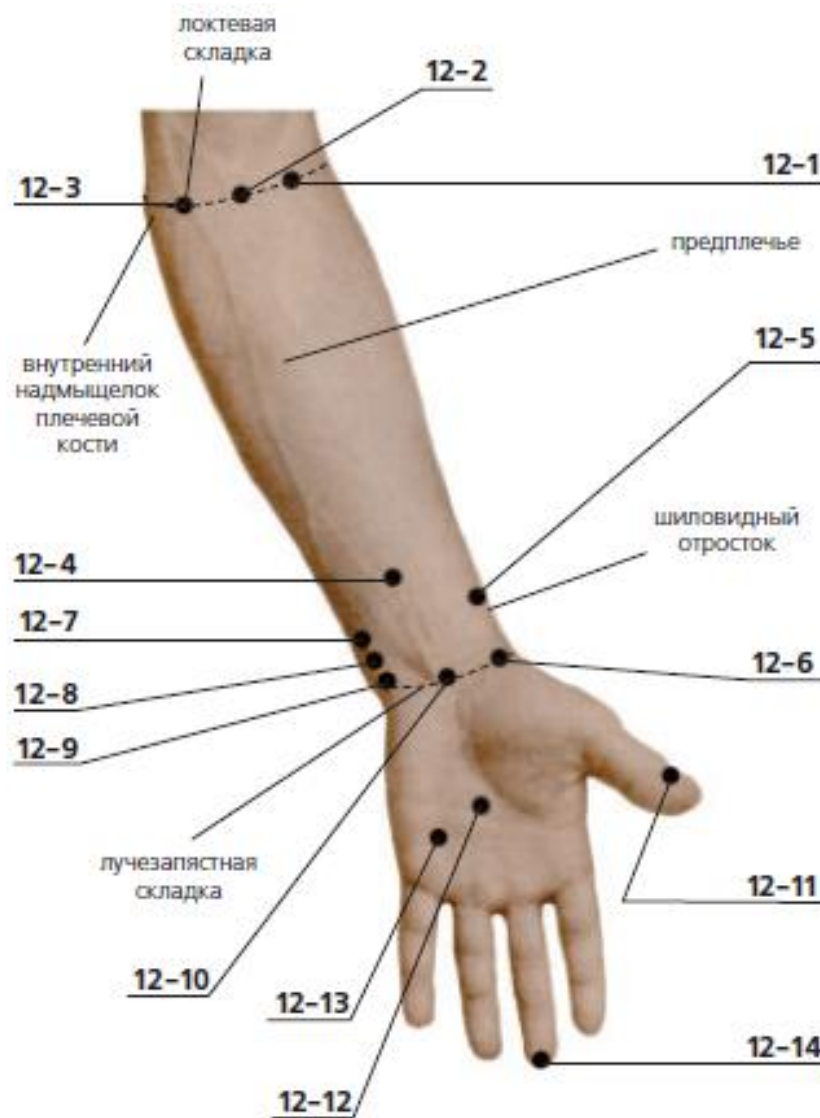
- 11-1** – in the middle of back surface of forearm, 3 chon upper from radiocarpal crease
- 11-2** – in the middle of back surface of forearm, 2 chon upper from radiocarpal crease
- 11-3** – on back surface of forearm in the center of radiocarpal crease
- 11-4** – on the lateral surface of second finger, between first and second fingers, in fossa
- 11-5** – on external side of V finger, in fossa, on the border palm and dorsum
- 11-6** – at the internal angle of nail of V finger
- 11-7** – at external angle of nail of IV finger
- 11-8** – at internal angle of nail of II finger

Лучезапястная складка - carpal fold // Боковая поверхность второго пальца - lateral surface of the second finger



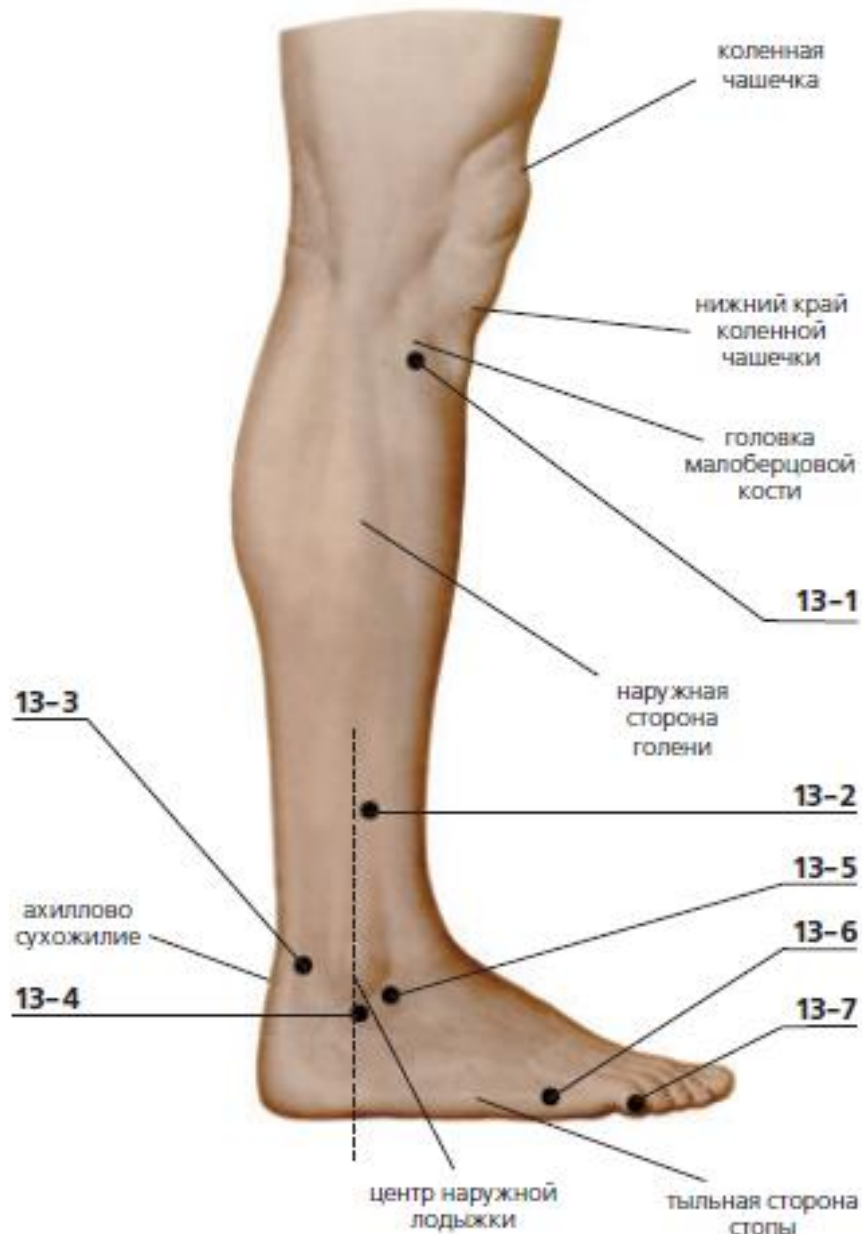- 12-1 – 1 chon from 12-2 area on elbow crease
- 12-2 – in the middle of elbow crease
- 12-3 – 1 chon from 12-2 area to the side of medial epicondyle on elbow crease
- 12-4 – 2 chon upper from radiocarpal crease, in the middle of forearm
- 12-5 – 1,5 upper from radiocarpal crease, a little above styloid process of ulna, in the fossa
- 12-6 – a little below styloid process of ulna, on radiocarpal crease
- 12-7 – 1 chon upper from radiocarpal crease, in fossa between two tendons
- 12-8 – 0,5 chon upper from radiocarpal crease, in fossa between two tendons
- 12-9 – on radiocarpal crease, over pisiform bone
- 12-10 – in the middle of radiocarpal crease, in the fossa between two tendons
- 12-11 – at external angle of I finger's nail
- 12-12 – in the center of palm, between the ends of III and IV fingers on bent fingers
- 12-13 – between the ends of IV and V fingers on bent fingers
- 12-14 – on the end of III finger

Локтевая складка - elbow crease // Предплечье - forearm // Шиловидный отросток - styloid process



- 13-1** – on the external side of leg, 2 chon below from low edge of patella
- 13-2** – 3 chon upper from the center of lateral malleolus and 0,5 chon ahead
- 13-3** – in the fossa between lateral malleolus and Achilles tendon
- 13-4** – under lateral malleolus
- 13-5** – forward from a zone 13-4, in fossa (at anterior margin of lateral malleolus)
- 13-6** – at the basis of V toe, in fossa, on border line between dorsum and sole
- 13-7** – on external corner of the nail fifth toe

Коленная чашечка - knee cap // Нижний край коленной чашечки - lower edge of the kneecap
 // Головка малоберцовой кости - head of fibula // Наружная сторона голени - outer side of lower leg // Ахиллово сухожилие - achilles tendon // Центр наружной лодыжки - outer ankle center // Тыльная сторона стопы - Back side of the foot

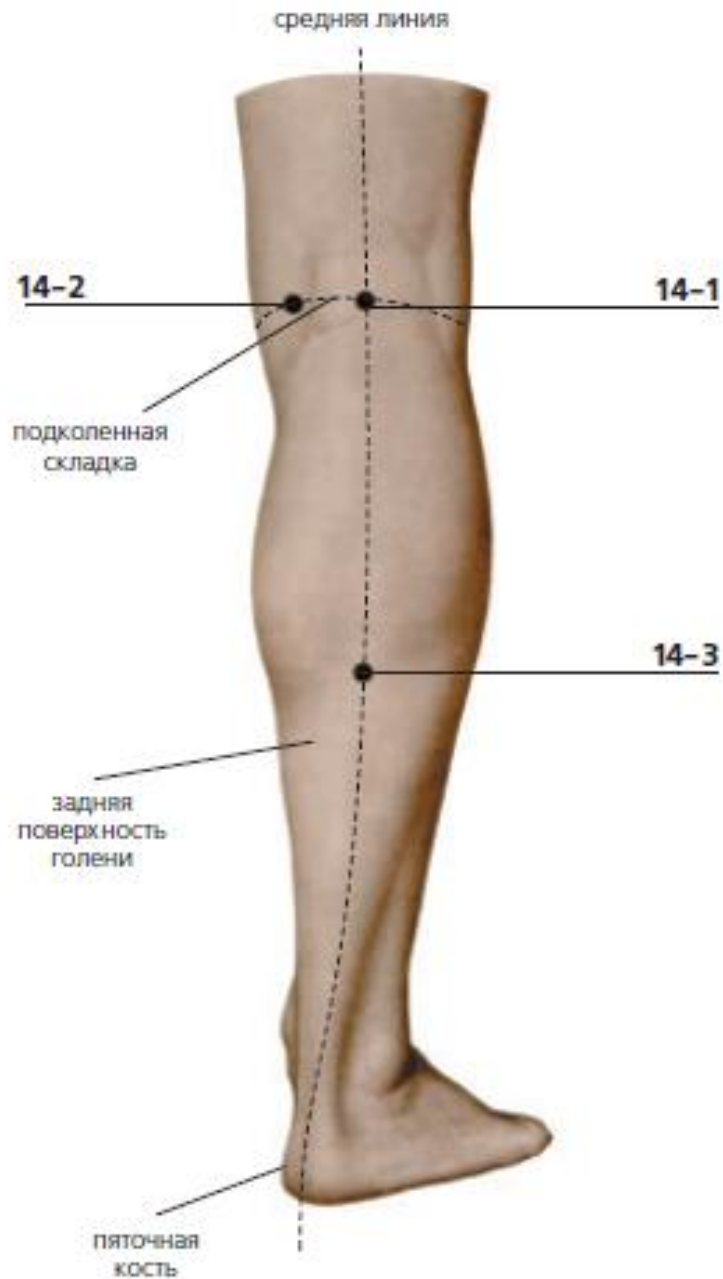


14-1 – in the center of popliteal fossa. It is easy to find point on bent knee joint

14-2 – on popliteal crease, 1 chon from 14-1 between tendons on the pulsation of arteries. It is easy to find point when someone flexes the leg in knee joint

14-3 – on midline of posterior side of leg, 7 chon below from 14-1

Подколенная складка - popliteal crease // Задняя поверхность голени - Back surface of the lower leg // Пяточная кость - calcaneus



15-1 – behind of tibia, 3 chon upper from the center of medial malleolus, on muscle. The area is painful on palpation

15-2 – 2 chon upper from the center of medial malleolus and a little behind (in the place where gastrocnemius muscle transforms into Achilles tendon).

15-3 – between medial malleolus and Achilles tendon, in fossa

15-4 – 0,5chon below from medial malleolus

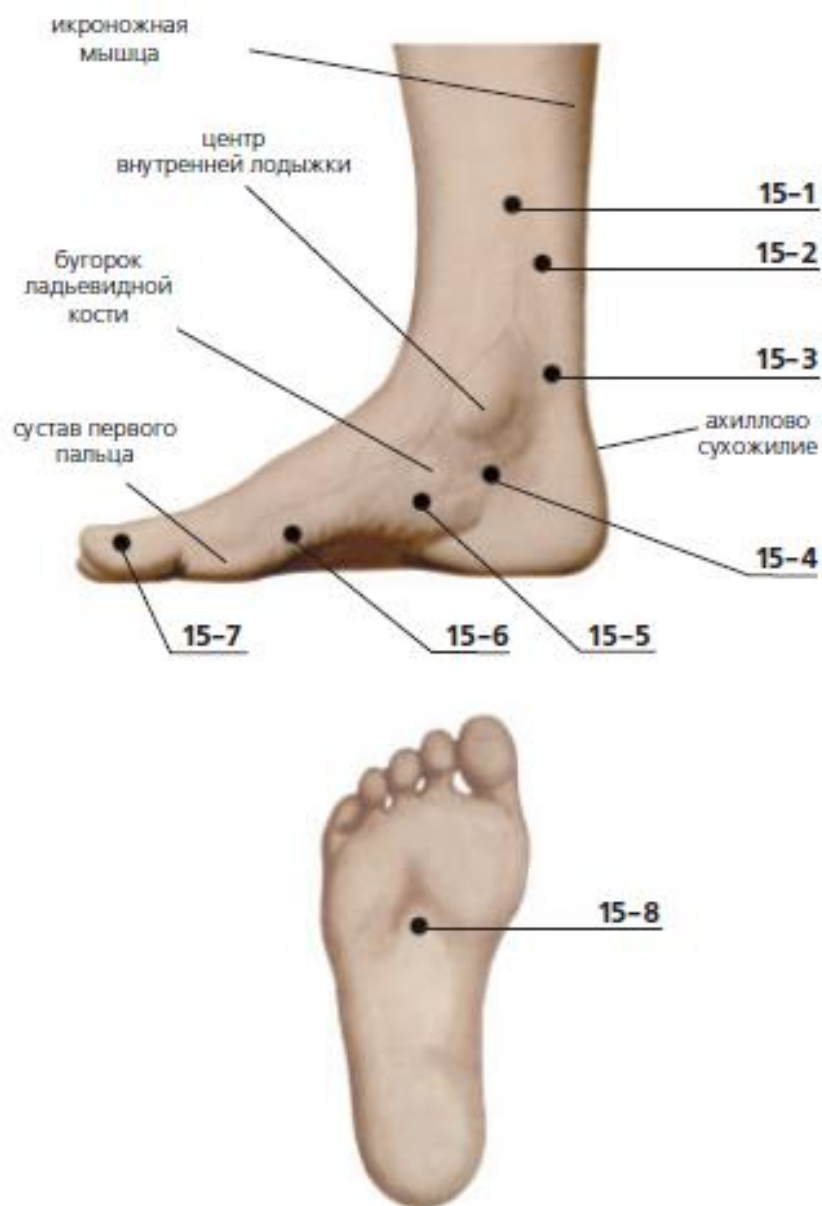
15-5 – in front of 15-4, a little below tubercle of navicular bone, in fossa Forward from a zone 2-4

15-6 – 1 chon behind of I interphalangeal joint

15-7 – on internal side of I toe's nail

15-8 – in the center of sole, in fossa. The area is painful on palpation.

Икроножная мышца - calf muscle // Центр внутренней лодыжки - center of the inner ankle // Бугорок ладьевидной кости - tubercle of the scaphoid // Сустав первого пальца - joint of the first finger



16-1 – 3 chon below from low margin of patella and 1 chon far from tibial crest. The area is painful on pressing.

16-2 – 8 chon upper from the center of lateral malleolus and 2 chon far from crest.

16-3 – on dorsal flexion of foot, in fossa, along the line of II toe.

16-4 – 1 chon upper from 16-5

16-5 – in the crease between second and third toes joints, in fossa

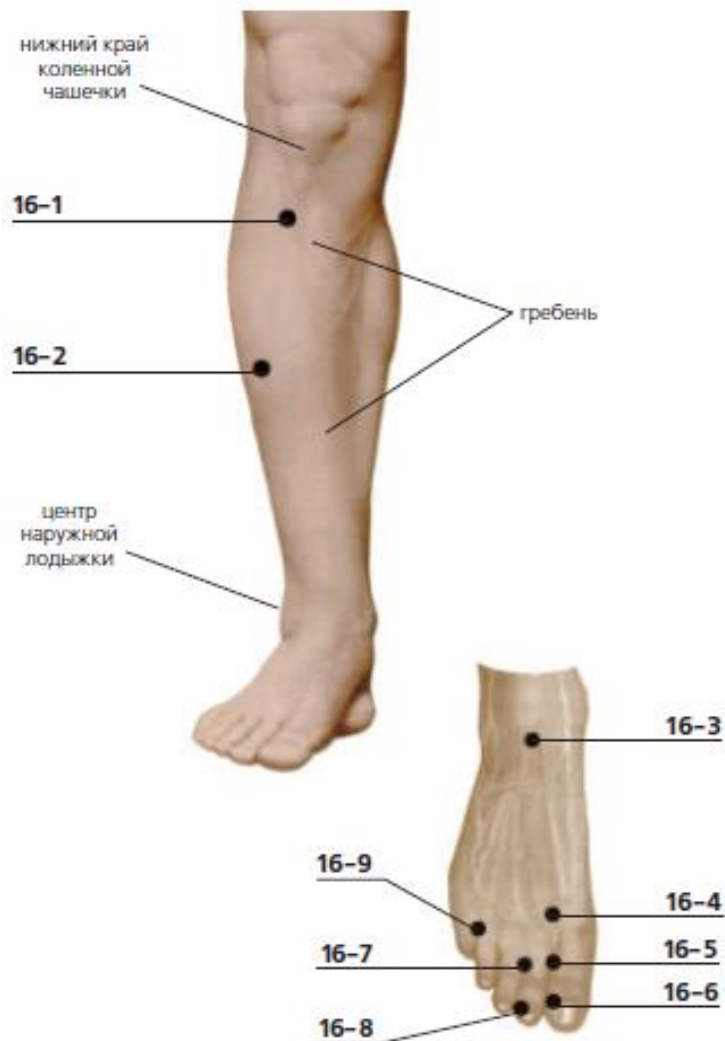
16-6 – on external angle of first toenail

16-7 – in the crease between second and third toes joints

16-8 – on external angle of second toenail

16-9 – on the crease between fourth and fifth toes joints

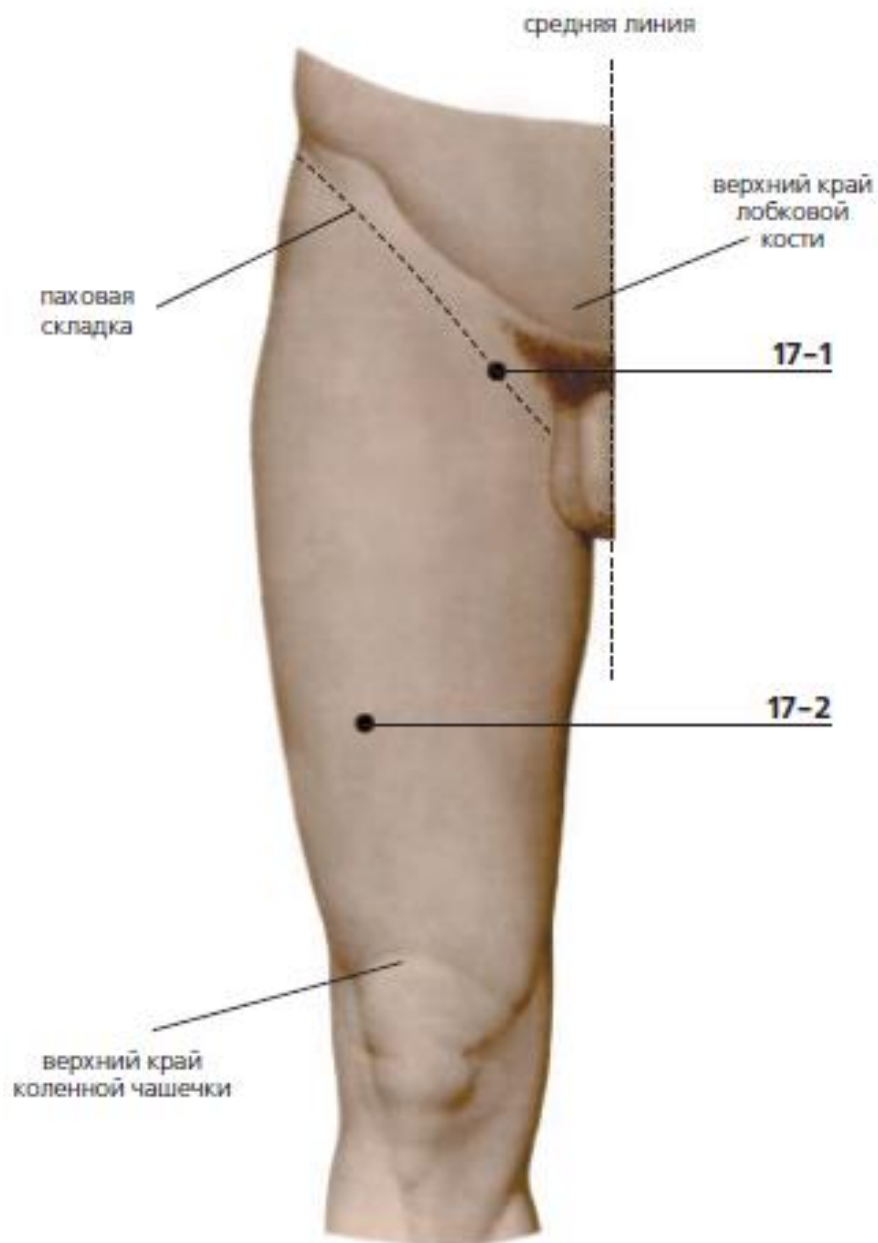
Гребень - crest



17-1 – 2 chon lower from upper margin of pubic bone and 2,5 chon far from midline, low part of inguinal fold

17-2 – on anterolateral side of femur, 6 chon upper from upper margin of patella. The area is detected on bent knee.

Верхний край коленной чашечки - upper edge of the kneecap



18-1 – in the middle of distance between coccyx and anus

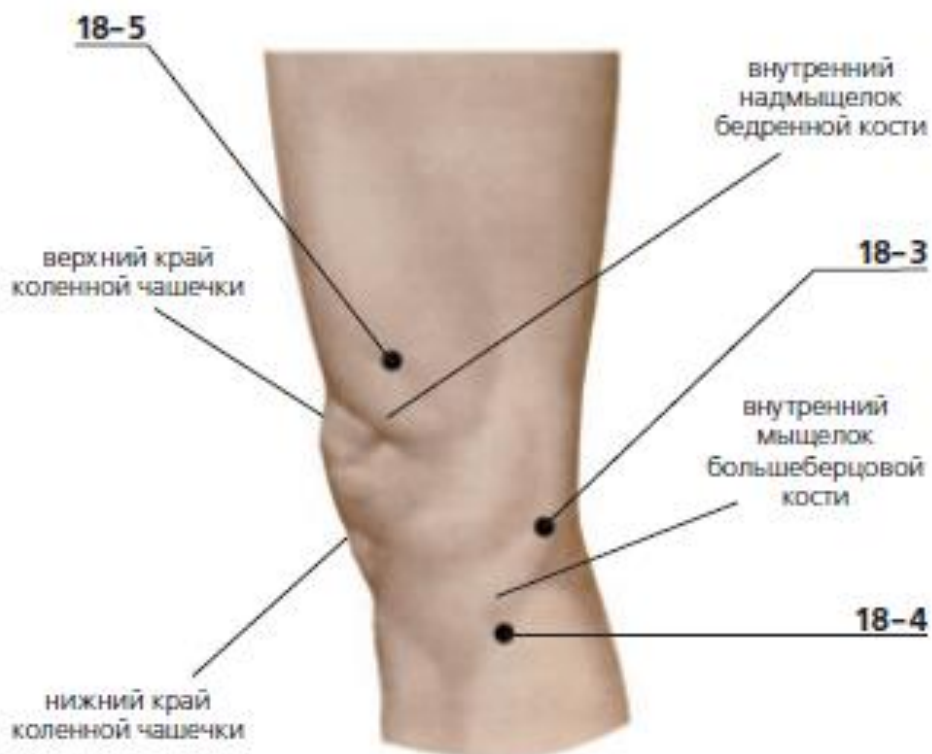
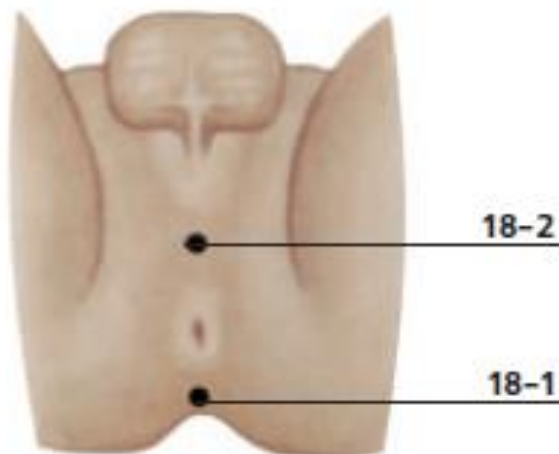
18-2 – between genitalia and anus

18-3 – on internal surface of knee joint at the end of popliteal crease. The area is detected on bent knee. The zone is defined(determined) at the bent knee

18-4 – 2 chon below low margin of patella, in fossa under bone (medial condyle of tibia). The area is detected on bent knee.

18-5 – 2 chon upper from the center of upper margin of patella and 2 chon inside, on muscle. The area is detected on bent knee.

Внутренний надмыщелок бедренной кости - internal epicondyle of the femur // Внутренний мыщелок большеберцовой кости - internal condyle of the tibia



Recommended zones for electromagnetic exposure

Start to expose from “red” zones. Hold the apparatus for 2 minutes. Then continue on “blue” zones. Slowly move the apparatus under the skin involve the zones of forehead, nose, cheeks, chin.

The movement should be light. Try not to tighten the skin. After therapeutic session apply skin lotion.

